Systematic Review and Meta-Analysis

Medicine

OPEN

MRI measurements of brain hippocampus volume in relation to mild cognitive impairment and Alzheimer disease

A systematic review and meta-analysis

Gaofeng Rao, MS[a], Hui Gao, BS[b], Xiaoyang Wang, BS[a], Jinchao Zhang, BS[a], Miaoqing Ye, BS[a], Liyuan Rao, BS[c,*]

Abstract

Background: This is the first meta-analysis conducted to compare the hippocampal volume measured by magnetic resonance imaging (MRI) in healthy normal subjects, mild cognitive impairment (MCI) and Alzheimer disease (AD), and to analyze the relationship between hippocampal volume changes and MCI and AD.

Methods: English literatures published from January 2004 to December 2006 were extracted from PubMed, Embase, Wanfang Medical, and China National Knowledge Infrastructure databases. Statistical analysis was carried out with Stata/SE 16.0 software.

Results: The smaller the volume of the hippocampus measured by MRI, the more severe the cognitive impairment or AD. Different MRI post-measurement correction methods have different measurement results: Left hippocampal volume measured by MRI Raw volume method is negatively correlated with MCI and AD (OR [odds ratio] = 0.58, 95%CI [confidence interval]: 0.42, 0.75) right hippocampal volume measured was not associated with MCI OR AD (OR = 0.87, 95%CI: 0.56, 1.18); left hippocampal volume measured by MRI total intracranial volume (TIV) Correction was not associated with MCI and AD (OR = 0.90, 95%CI: 0.62, 1.19), measured right hippocampal volume was not associated with MCI OR AD (OR = 0.81, 95%CI: 0.49, 1.12); left hippocampal volume measured by MRI TIV Correction was not associated with MCI and AD (OR = 0.90, 95%CI: 0.62, 1.19), measured right hippocampus volume was negatively associated with MCI and AD (OR = 0.49, 95%CI: 0.35, 0.62).

Conclusion: The shrinkage of hippocampus volume is closely related to MCI and AD. MRI measurement of hippocampus volume is not only an auxiliary diagnostic tool for MCI and AD, but also a good prognosis assessment tool.

Abbreviations: AD = Alzheimer disease, CI = confidence interval, ICA = icoronal intracranial area, MCI = mild cognitive impairment, MRI = magnetic resonance imaging, NOS = Newcastle-Ottawa Scale, OR = odds ratio, TIV = total intracranial volume.

Keywords: Alzheimer disease, hippocampus, meta-analysis, mild cognitive impairment, MRI

1. Introduction

Alzheimer disease (AD) refers to the specific onset and process of age-related cognitive and functional decline, which eventually leads to death.[1,2] Alois Alzheimer first described the condition in 1906 when he described the case of Auguste Deter, a 51-year-old woman who suffered from cognitive impairment, disorientation, delusions, and other behavioral changes.[3] Neuropathological assessment of AD reveals diffuse brain atrophy and "specific changes in cortical cell clusters".[4] Dementia is a progressive syndrome of global cognitive impairment. In 2010, more than 35 million people worldwide were estimated to be living with dementia. It has been reported that some people with mild cognitive impairment (MCI) progress to dementia, but others remain stable or return to full function.[5,6]

The formation and accumulation of abnormally folded proteins is the most prominent histopathological feature of AD.[7] In the case of AD, there is an increased formation of intracellular neurofibrillary tangles and extracellular amyloid plaques in the

GR and HG contributed equally to this work.

This meta-analysis was supported by the Taizhou Science and Technology Plan Project (No. 1902ky147).

The authors have no conflicts of interest to disclose.

The datasets generated during and/or analyzed during the current study are not publicly available, but are available from the corresponding author on reasonable request.

[a] Department of Rehabilitation, Taizhou Integrated Chinese and West Medicine Hospital, Taizhou, Zhejiang, China, [b] Department of Neurology, Taizhou Integrated Chinese and West Medicine Hospital, Taizhou, Zhejiang, China, [c] Department of Gynecology, Jinxi Maternal and Child Family Planning Service Center, Fuzhou, Jiangxi, China.

*Correspondence: Liyuan Rao, Department of Gynecology, Jinxi Maternal and Child family planning Service Center, No.14 Baima Road, Xiugu Town, Jinxi County, Fuzhou, Jiangxi, China (e-mail: m13755989500@163.com).

Copyright © 2023 the Author(s). Published by Wolters Kluwer Health, Inc. This is an open-access article distributed under the terms of the Creative Commons Attribution-Non Commercial License 4.0 (CCBY-NC), where it is permissible to download, share, remix, transform, and buildup the work provided it is properly cited. The work cannot be used commercially without permission from the journal.

How to cite this article: Rao G, Gao H, Wang X, Zhang J, Ye M, Rao L. MRI measurements of brain hippocampus volume in relation to mild cognitive impairment and Alzheimer disease: A systematic review and meta-analysis. Medicine 2023;102:36(e34997).

Received: 9 June 2023 / Received in final form: 4 August 2023 / Accepted: 8 August 2023

http://dx.doi.org/10.1097/MD.0000000000034997

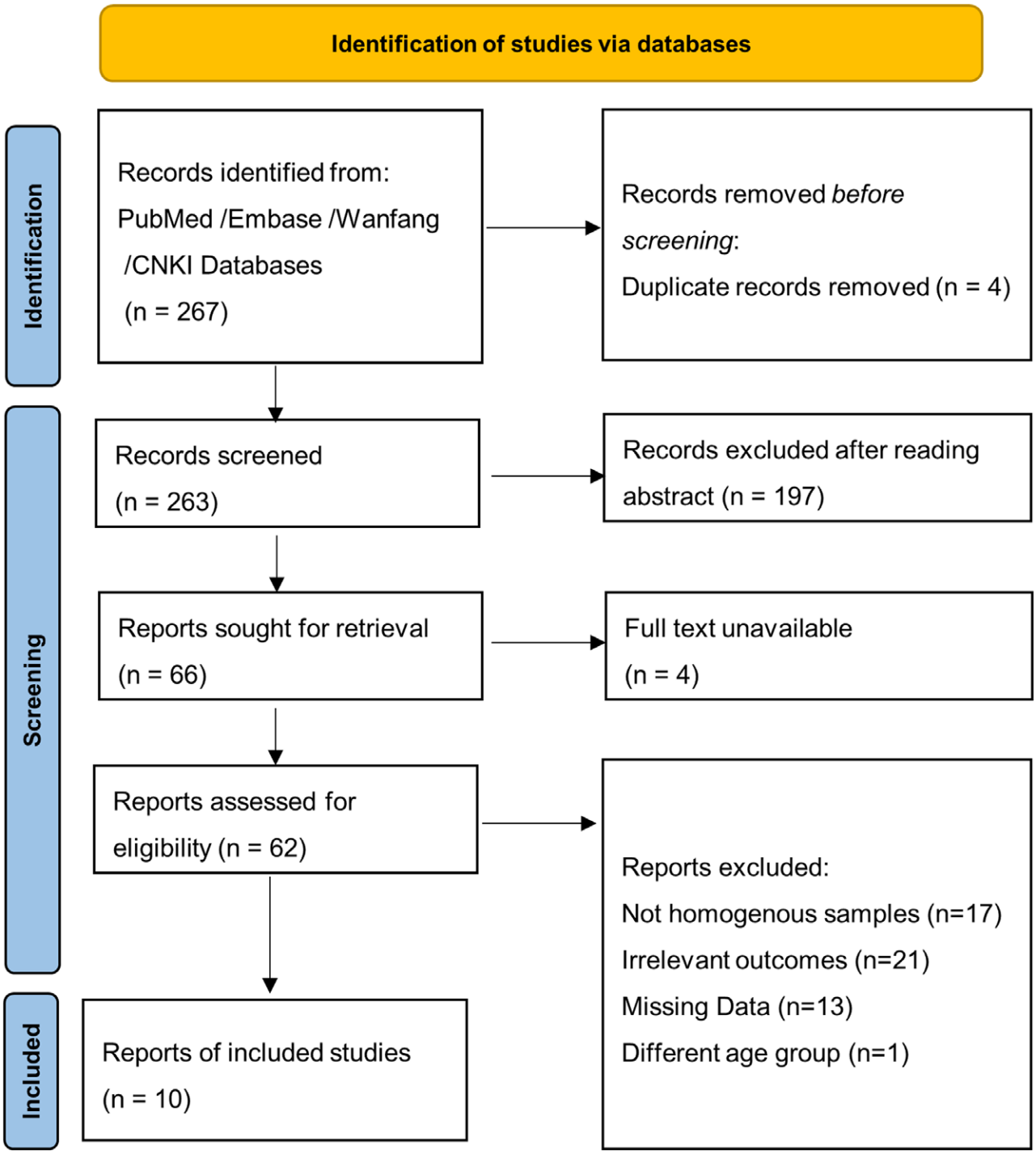

Figure 1. Literature screening flow chart.

brain.[8,9] This is manifested in extracellular plaques of accumulated beta-amyloid protein, intracellular neurofibrillary tangles containing hyperphosphorylated tau protein, and severe loss of basal forebrain cholinergic neurons that innervate the hippocampus and neocorticum. Beta-amyloid protein accumulation may trigger or contribute to neurodegenerative processes.[10]

Adult hippocampal neurogenesis is an early key event in the process of AD.[11] Although no causal link has been established, various key molecules in the pathogenesis of AD have been shown to positively or negatively influence the generation of new neurons. From a functional perspective, hippocampal neurogenesis plays an important role in structural plasticity and network maintenance. Some associations have been observed between volume changes in the hippocampus and MCI and AD.[11–13] However, there is still a lack of systematic research and evaluation.

Therefore, this is the first meta-analysis that collected magnetic resonance imaging (MRI) measurements of hippocampus volume in healthy subjects, MCI, and AD, with the aim of comparing the differences among the 3, and evaluating the association of hippocampus volume changes with MCI and AD.

Table 1

Basic features included in the study.

Study and year	Correction method	Patients	Patient		Control	
			N	Age	N	Age
Barnes et al[18]	Raw volume	AD	32	59	50	59.6
Basso et al[10]	Raw volume	AD	56	71.2	42	73.2
Head et al[17]	Raw volume	AD	25	77	25	77
Head et al[17]	Raw volume	MCI	25	78	25	76
Ridha et al[11]	TIV Correction	AD	7	49.8	25	46.5
Scher et al[14]	TIV Correction	AD	24	82.5	102	82.8
Teipel et al[19]	TIV Correction	MCI	34	69	22	61.5
Van de Pol et al[15]	TIV Correction	MCI	103	77	73	78
Sandstrom et al[16]	ICA Correction	AD	20	75	20	71.2
Wang PN et al[12]	ICA Correction	AD	65	76.4	20	75.1
Wang PN et al[12]	ICA Correction	AD	58	76.3	20	75.1
Pennannen et al[13]	ICA Correction	MCI	48	71.1	59	72.7
Pennannen et al[13]	ICA Correction	MCI	65	72.8	59	72.7

AD = Alzheimer disease, ICA = icoronal intracranial area, MCI = mild cognitive impairment, TIV = total intracranial volume.

2. Materials and methods

2.1. Literature search strategy

This Meta-analysis was conducted in strict accordance with Preferred Reporting Items for Systematic Reviews and Meta-Analyses regulations. In this meta-analysis, English literature published from January 2004 to December 2006 was extracted from PubMed, Embase, Wanfang Medical, and China National Knowledge Infrastructure databases. The literature search mainly adopts the combination of subject words and unqualified search, and the English search keywords are: "Hippocampus" (as a Medical Subject Heading [MeSH] term) and "AD" (as a [MeSH] term) and "Volume". The title and abstract were examined to determine whether they could be included in the meta-analysis, and the full text of candidate articles were examined for further confirmation. Additional studies were identified from the reference list of key studies.

2.2. Inclusion and exclusion criteria

Inclusion criteria:

(1) Type of research design: original observational research method, full text available.
(2) Subjects: patients with MCI or AD, and normal controls were reported.
(3) Hippocampal volume was calculated based on MRI measurements.
(4) Original study with no missing data.

Exclusion criteria:

(1) Duplicate articles or no full text;
(2) Non-randomized controlled trials;
(3) Research on data missing or errors that cannot be completed and corrected;
(4) Lack of outcome indicators required by this meta-analysis;
(5) Letters, case reports, reviews, practice guidelines, etc;
(6) Included subjects included MCI or AD patients with other underlying diseases and normal control group;
(7) All animal experiments.

2.3. Data extraction

Data were collected by 2 independent investigators on date of publication, author, study design, study population and mean age, sample size, and volume of MRI measurements of the left and right hippocampus respectively.

2.4. Quality evaluation

This meta-analysis was conducted by 2 independent researchers who assessed the quality of the studies in our analysis based on the Newcastle-Ottawa Scale (NOS).[12] The NOS scale consisted of 3 dimensions and 8 items: 4 items for the selection of research objects, 1 item for inter-group comparability and 3 items for outcome measurement. Except for the item of comparability between groups, the maximum score is 2 points, and the other items can be scored 1 point, the score range is 0~9 points. The higher the total score, the higher the quality of the study. Studies with a score of 6 to 9 are considered to be of high quality and those with a score of 0 to 5 are considered to be of low quality. Studies were scored independently by 2 researchers and any differences between reviewers were resolved by consensus or by a third reviewer.

2.5. Statistic analysis

In this meta-analysis, the combined odds ratio (OR) and 95% confidence interval (CI) were obtained by using Stata/SE 16.0 software, with reference to calculation methods in other literature, to estimate the association between left and right hippocampus volume changes and MCI and AD, respectively. The outcome indicators in this meta-analysis were continuous variables, expressed by mean and 95%CI. Q test was used to test the heterogeneity between studies. If $I^2 < 50\%$ and $P > .1$, the heterogeneity between studies was small, and fixed effects model was used. Otherwise, the random effects model is used to calculate the combined effect size. According to different Correction methods, further subgroup analysis was performed in this meta-analysis, which was divided into Raw volume, total intracranial volume (TIV) Correction and icoronal intracranial area (ICA) Correction methods. Forest maps were used to describe the statistical results of the meta-analysis. In addition, funnel plots were drawn to assess publication bias.

3. Results

3.1. Literature search and screening results

A total of 267 studies were extracted from the 4 databases through the above retrieval method, and 121 original studies were extracted after the exclusion of duplicate articles. By reviewing the title, keywords and abstract, 66 of the studies were identified as likely to be relevant to the research topic. We searched further for the full text of these studies and got the full text of 62 studies in total. We excluded another 52 studies

Table 2

Quality evaluation of included studies.

First author	Quality evaluation score (NOS)	Selection of research subjects					Measurement of outcome		
		Representative of experimental group (AD/MCI)	Representative of control group	Definition of Experimental Group (AD/MCI)	Definition of control group	Comparability between groups	Outcome index measurement	Follow-up time	Follow-up of integrity
Barnes et al[18]	8	Uncertainty	Good	Clarity	Clarity	Good	Low risk	Long	Good
Basso et al[10]	6	Good	-	Clarity	-	Uncertainty	Low risk	Long	Good
Head et al[17]	9	Good	Good	Clarity	Clarity	Good	Low risk	Long	Good
Ridha et al[11]	8	Good	Good	Clarity	Clarity	Uncertainty	Low risk	Long	Good
Scher et al[14]	5	Good	-	Clarity	-	Uncertainty	Low risk	Long	Uncertainty
Teipel et al[19]	7	Uncertainty	Good	Clarity	Clarity	Uncertainty	Low risk	Long	Good
Van de Pol et al[15]	7	Good	Uncertainty	Clarity	Clarity	Good	Low risk	Long	Uncertainty
Sandstrom et al[16]	5	Good	-	Clarity	-	Uncertainty	Low risk	Long	Good
Wang PN et al[12]	8	Good	Good	Clarity	Clarity	Uncertainty	Low risk	Long	Good
Pennannen et al[13]	6	Good	-	Clarity	-	Uncertainty	Low risk	Long	Good

AD = Alzheimer disease, MCI = mild cognitive impairment, NOS = Newcastle-Ottawa Scale.

based on inclusion and exclusion criteria. Finally, a total of 10 studies[10–19] were included in this meta-analysis. The literature screening process is shown in Figure 1.

3.2. Basic features included in the study

All 10 literatures[14–23] included were original studies. They included 562 patients with AD or MCI and 542 normal healthy controls. The basic features of the included studies are shown in Table 1.

3.3. Quality evaluation of the included literature

The quality of the literatures was evaluated based on the NOS,[24] and the quality evaluation results of the included literatures were shown in Table 2.

3.4. Results of meta-analysis and sensitivity analysis

3.4.1. Relationship between left hippocampus volume measured by MRI and MCI and AD. Results of meta-analysis showed that the left hippocampus volume measured by MRI was negatively correlated with MCI and AD (OR = 0.77, 95%CI: 0.66, 0.88), as shown in Figure 2. The smaller the volume of the left hippocampus measured by MRI, the more severe the cognitive impairment or AD.

3.4.2. Relationship between left hippocampus volume measured by MRI and MCI and AD (raw volume). Results of meta-analysis showed that the left hippocampus volume measured by MRI Raw volume was negatively correlated with MCI and AD (OR = 0.58, 95%CI: 0.42, 0.75), as shown in Figure 3. The smaller the volume of the left hippocampus in the Raw volume method measured by MRI, the more severe the cognitive impairment or AD.

3.4.3. Relationship between left hippocampal volume measured by MRI and MCI and AD (TIV correction). Results of meta-analysis showed no correlation between left hippocampus volume measured by MRI TIV Correction and MCI and AD (OR = 0.90, 95%CI: 0.62, 1.19), as shown in Figure 4.

3.4.4. Relationship between left hippocampus volume measured by MRI and MCI and AD (ICA correction). Results of meta-analysis showed that the volume of the left hippocampus measured by MRI ICA Correction was not correlated with MCI and AD (OR = 0.92, 95th CI: 0.75, 1.09), as shown in Figure 5.

3.4.5. Relationship between right hippocampus volume measured by MRI and MCI and AD. Results of meta-analysis showed that the right hippocampus volume measured by MRI was negatively correlated with MCI and AD (OR = 0.61, 95%CI: 0.51, 0.71), as shown in Figure 6. The smaller the volume of the right hippocampus measured by MRI, the more severe the cognitive impairment or AD.

3.4.6. Relationship between right hippocampus volume measured by MRI and MCI and AD (raw volume). Results of meta-analysis showed that the right hippocampus volume measured by MRI Raw volume method was not correlated with MCI and AD (OR = 0.87, 95%CI: 0.56, 1.18), as shown in Figure 7.

3.4.7. Relationship between right hippocampal volume measured by MRI and MCI and AD (TIV correction). Results of meta-analysis showed no correlation between the right hippocampus volume measured by MRI TIV Correction and

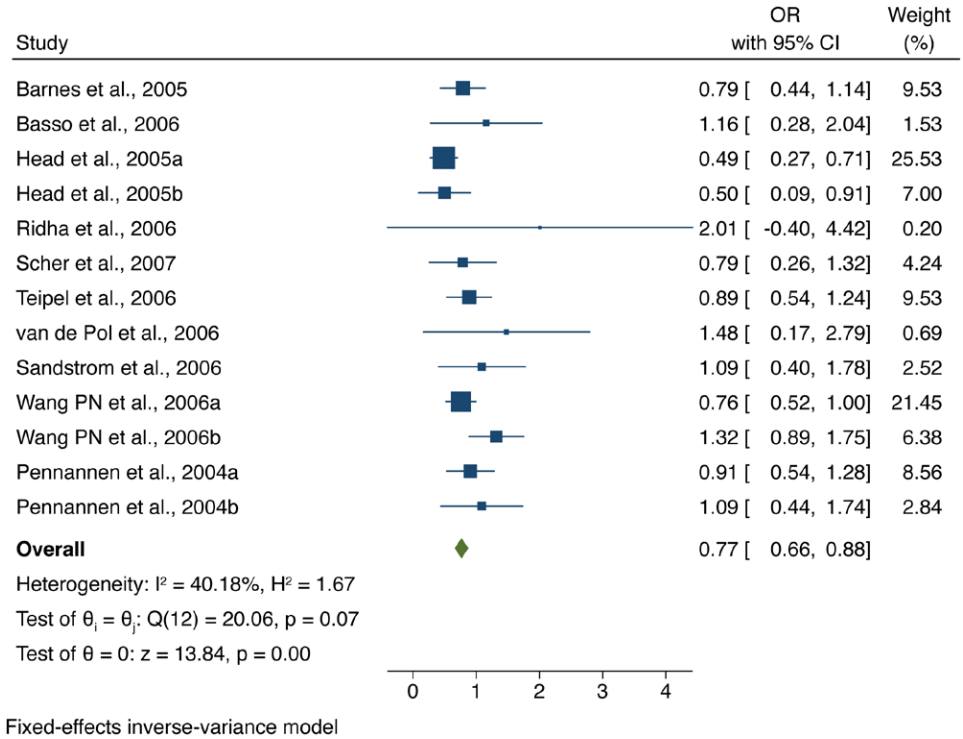

Figure 2. Forest map of the relationship between left hippocampus volume measured by MRI and mild cognitive impairment and Alzheimer disease. MRI = magnetic resonance imaging.

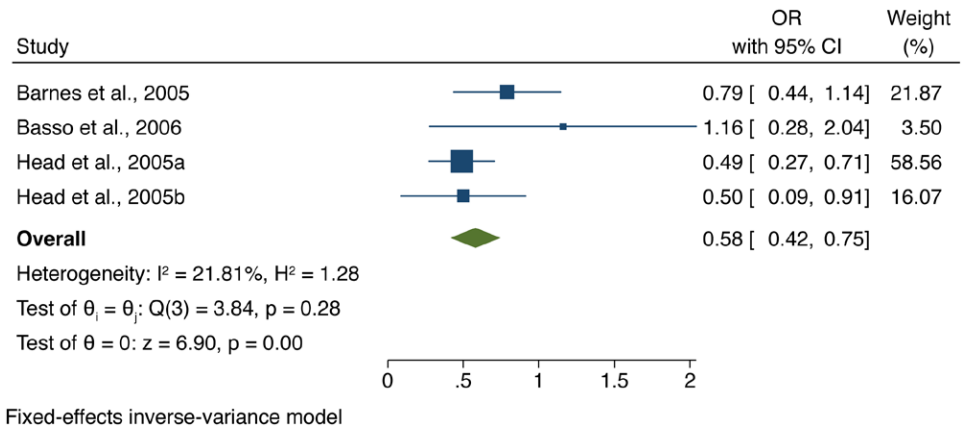

Figure 3. Forest map of the relationship between left hippocampus volume measured by MRI and mild cognitive impairment and Alzheimer disease. MRI = magnetic resonance imaging.

MCI and AD (OR = 0.81, 95%CI: 0.49, 1.12), as shown in Figure 8.

3.4.8. Relationship between right hippocampal volume measured by MRI and MCI and AD (ICA correction). Results of meta-analysis showed that the volume of the right hippocampus measured by MRI ICA Correction was negatively correlated with MCI and AD (OR = 0.49, 95%CI: 0.35, 0.62), as shown in Figure 9. The smaller the volume of the right hippocampus measured by MRI ICA Correction, the more severe the cognitive impairment or AD.

3.5. Publication bias

The funnel plot results showed a slight asymmetry (Figs. 10 and 11), and we speculated that there might be some publication bias.

4. Discussion

AD has been recognized as a global public health priority by the World Health Organization. It is an acquired progressive cognitive disorder that affects activities of daily living and is a major cause of dependence, disability and death.[4,25,26] Current estimates suggest that 44 million people worldwide are currently living with dementia. This number is expected to more than triple by 2050 as the population ages, when the annual cost of dementia in the United States alone could exceed $600 billion.[3,27] Although our understanding of the pathogenesis of AD and the concept of the disease has come a long way since 1907, when the first case of Alois Alzheimer was reported, the specific mechanism of the disease is still not particularly well understood.

MCI is a widely used term describing the intermediate stage from normal cognitive function to dementia.[6] The MCI concept is important to the field of aging and dementia for several

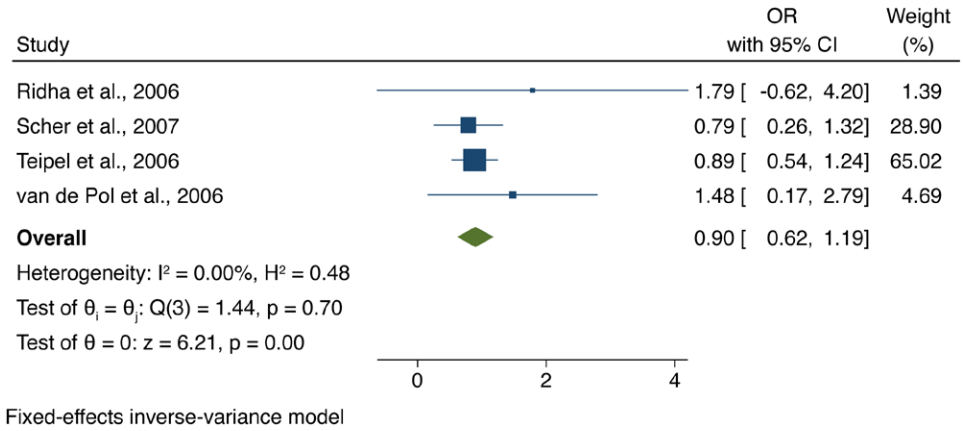

Figure 4. Forest map of the relationship between left hippocampal volume measured by MRI and mild cognitive impairment and Alzheimer's disease. MRI = magnetic resonance imaging.

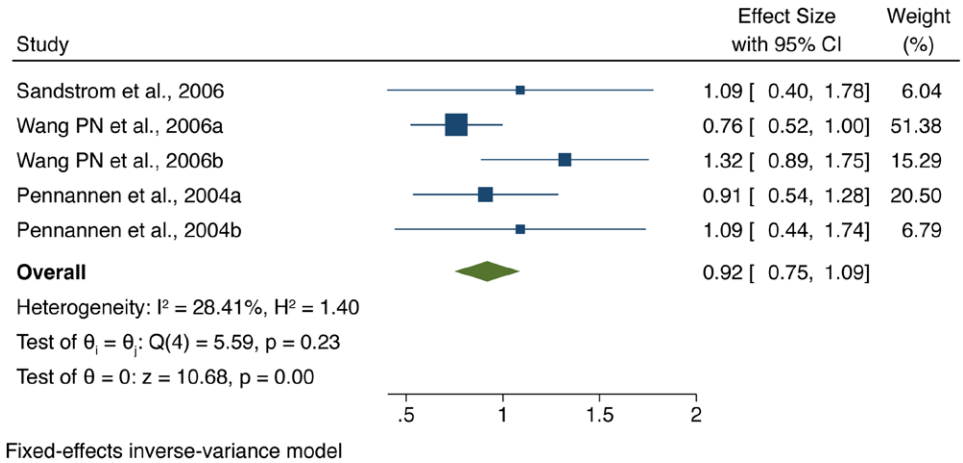

Figure 5. Forest map of the relationship between left hippocampus volume measured by MRI and mild cognitive impairment and Alzheimer disease. MRI = magnetic resonance imaging.

reasons. Subjects with MCI had a higher rate of progression to dementia in a relatively short period of time. Even among subjects who returned to normal cognition, the rate of subsequent MCI or dementia was higher than in those who never had MCI.[28] Research related to MCI has provided insights into the mechanisms of predementia disease.

Memory disorders are the core clinical symptom in MCI.[29,30] Dementia associated with AD and hippocampus shrinkage is associated with abnormal production, processing, and clearance of beta-amyloid and tau proteins. The deposition of beta-amyloid in the brain follows a distinct spatial progression from the cortex in the brain. The basal neocortex, spreads throughout the hippocampus, and eventually to the rest of the cortex. The spread of tau pathology through neural networks leads to a unique and consistent spatial progression of neurofibrillary tangles, beginning in the transent olfactory and hippocampal neurons. And spread above the primary region of the neocortex. Synaptic dysfunction and cell death are manifested by progressive loss of brain metabolic rate of glucose and progressive brain atrophy.[31]

The left and right hippocampus are located in the left and right hemispheres of the brain, respectively. The are different functions in different hippocampus and they belong to the limbic system. The right hippocampus contributes predominately to long-term memory tasks, while right hippocampal contributes to short-term memory tasks.[32] Some studies have found significant hippocampal shrinkage in the MCI and AD groups, possibly with some connection to neuron loss, since there was a strong correlation between the number of neurons and total hippocampal volume in AD patients and older subjects. Hippocampal CA1 subregion neurons were significantly reduced in AD patients.[12,33,34] In addition, autopsy studies have shown that this reduction occurs in the following order: control > patients with MCI > patients with mild AD.[12] Recently, more and more attention has been paid to the predictive role of the hippocampus in MCI and AD.

Therefore, in this meta-analysis, we performed a meta-analysis of studies on hippocampal volume measured by cross-sectional MRI, including those in patients with MCI or AD. This meta-analysis further explored the close relationship between hippocampus volume measured by MRI and AD and MCI.

The results showed that the smaller the left or right hippocampal volume measured by MRI, the more severe the cognitive impairment or AD, suggesting that hippocampal atrophy is one of the mechanisms of MCI or AD. However, different MRI post-measurement correction methods yielded different results: The left hippocampus volume measured by MRI Raw volume method was negatively correlated with MCI and AD (OR = 0.58, 95%CI: 0.42, 0.75) right hippocampal volume measured was not associated with MCI OR AD (OR = 0.87, 95%CI: 0.56, 1.18); left hippocampal volume measured by MRI TIV Correction was not associated

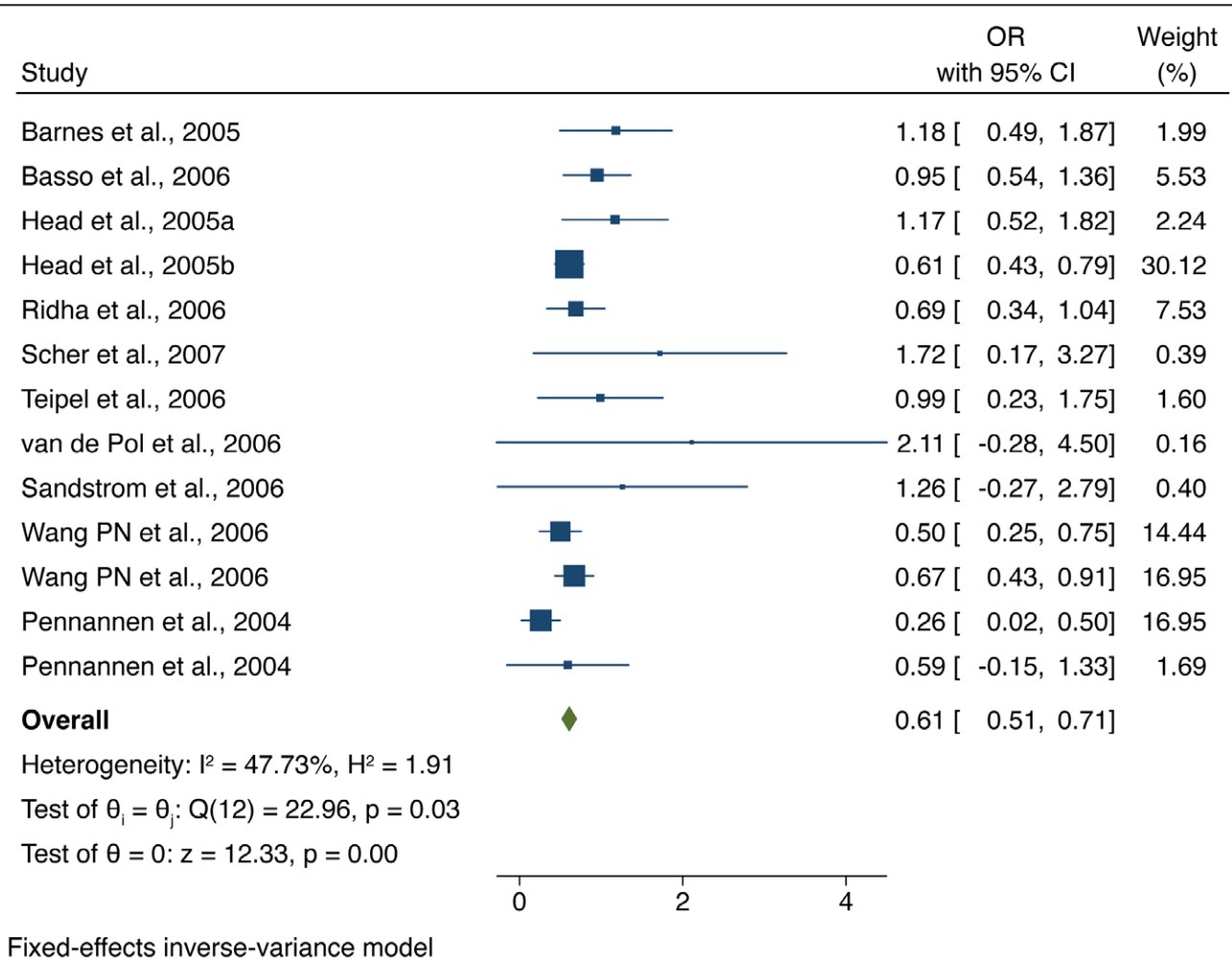

Figure 6. Forest map of the relationship between the right hippocampus volume measured by MRI and mild cognitive impairment and Alzheimer disease. MRI = magnetic resonance imaging.

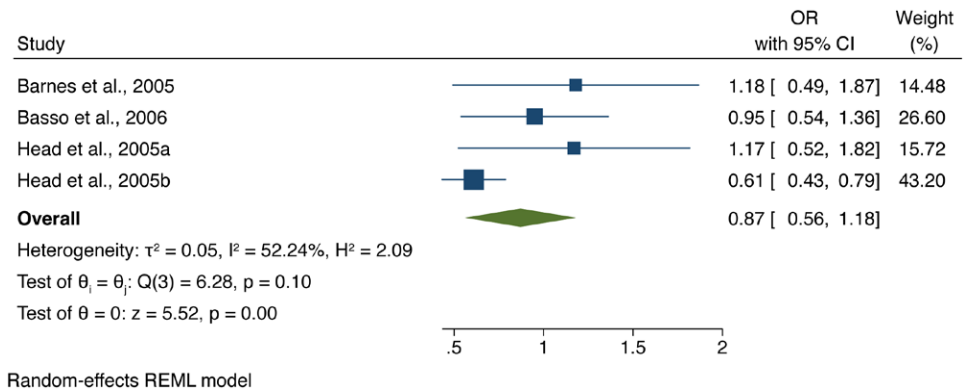

Figure 7. Forest map of the relationship between the right hippocampus volume measured by MRI and mild cognitive impairment and Alzheimer disease. MRI = magnetic resonance imaging.

with MCI and AD (OR = 0.90, 95%CI: 0.62, 1.19), measured right hippocampal volume was not associated with MCI OR AD (OR = 0.81, 95%CI: 0.49, 1.12); left hippocampal volume measured by MRI TIV Correction was not associated with MCI and AD (OR = 0.90, 95%CI: 0.62, 1.19), measured right hippocampus volume was negatively associated with MCI and AD (OR = 0.49, 95%CI: 0.35, 0.62).

However, there are some limitations in this meta-analysis. First, we only included the papers published from 2004 to 2006. The time period of this meta-analysis was limited. Second, a total of 1104 participants were included. The sample size was limited in this meta-analysis, which mean the results needed larger sample sizes to be further validated and supplemented. Furthermore, the age of participants in some included papers was quite different from other studies, which might lead the

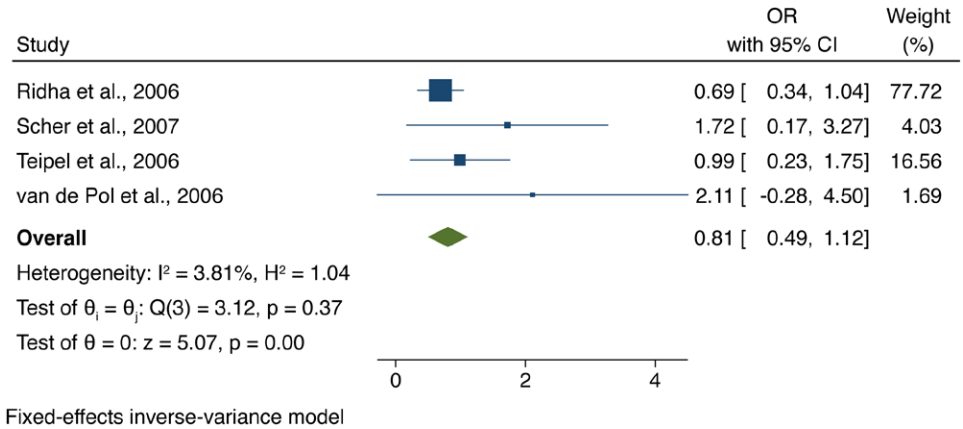

Figure 8. Forest map of the relationship between the right hippocampus volume measured by MRI and mild cognitive impairment and Alzheimer disease. MRI = magnetic resonance imaging.

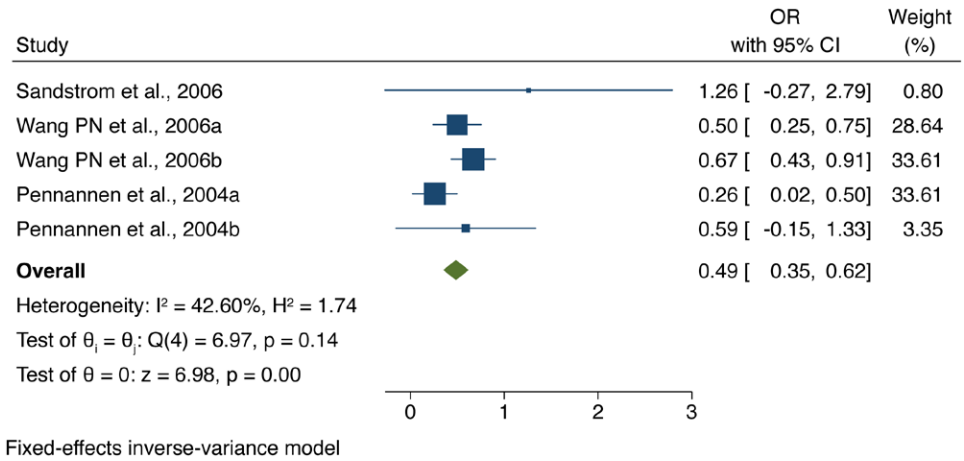

Figure 9. Forest map of the relationship between the right hippocampus volume measured by MRI and mild cognitive impairment and Alzheimer disease. MRI = magnetic resonance imaging.

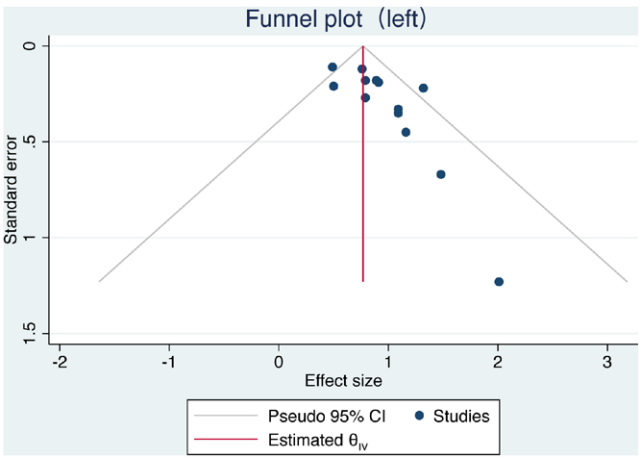

Figure 10. Funnel chart (on the left side of the hippocampus).

bias. Fourthly, the included papers were cross-sectional studies. So, we summarize the causal relationship between hippocampal volume and MCI or AD by MRI.

In conclusion, this meta-analysis has further clarified the mechanism of MCI and AD, and we speculate that the significant atrophy of the hippocampus may have some connection with the loss of neurons. MRI can be used for diagnosis and an objective assessment of the progression of MCI and AD patients to understand the patient condition. MRI measurement of hippocampus volume is not only an auxiliary diagnostic tool for MCI and AD, but also a good prognosis assessment tool.

Author contributions

Conceptualization: Gaofeng Rao.
Data curation: Gaofeng Rao, Hui Gao, Jinchao Zhang, Miaoqing Ye.
Formal analysis: Hui Gao.
Funding acquisition: Liyuan Rao.
Investigation: Miaoqing Ye.
Methodology: Jinchao Zhang.
Project administration: Liyuan Rao.
Resources: Xiaoyang Wang.
Software: Hui Gao.
Supervision: Jinchao Zhang, Liyuan Rao.
Validation: Xiaoyang Wang.
Visualization: Xiaoyang Wang, Liyuan Rao.
Writing – original draft: Gaofeng Rao, Hui Gao, Liyuan Rao.
Writing – review & editing: Xiaoyang Wang, Jinchao Zhang, Miaoqing Ye, Liyuan Rao.

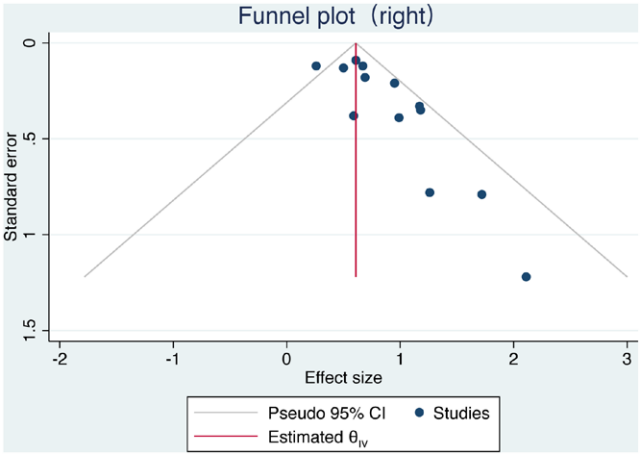

Figure 11. Funnel chart (on the right side of the hippocampus).

References

[1] Ossenkoppele R, van der Kant R, Hansson O. Tau biomarkers in Alzheimer's disease: towards implementation in clinical practice and trials. Lancet Neurol. 2022;21:726–34.

[2] Toups K, Hathaway A, Gordon D, et al. Precision medicine approach to Alzheimer's disease: successful pilot project. J Alzheimers Dis JAD. 2022;88:1411–21.

[3] Janoutová J, Machaczka O, Zatloukalová A, et al. Is Alzheimer's disease a type 3 diabetes? A review. Cent Eur J Public Health. 2022;30:139–43.

[4] Soria Lopez JA, González HM, Léger GC. Alzheimer's disease. Handb Clin Neurol. 2019;167:231–55.

[5] Delgado-Alvarado M, Gago B, Navalpotro-Gomez I, et al. Biomarkers for dementia and mild cognitive impairment in Parkinson's disease. Mov Disord Off J Mov Disord Soc. 2016;31:861–81.

[6] Morley JE. An overview of cognitive impairment. Clin Geriatr Med. 2018;34:505–13.

[7] Dá Mesquita S, Ferreira AC, Sousa JC, et al. Insights on the pathophysiology of Alzheimer's disease: the crosstalk between amyloid pathology, neuroinflammation and the peripheral immune system. Neurosci Biobehav Rev. 2016;68:547–62.

[8] Haass C, Selkoe DJ. Soluble protein oligomers in neurodegeneration: lessons from the Alzheimer's amyloid beta-peptide. Nat Rev Mol Cell Biol. 2007;8:101–12.

[9] Querfurth HW, LaFerla FM. Alzheimer's disease. N Engl J Med. 2010;362:329–44.

[10] Kar S, Slowikowski SPM, Westaway D, et al. Interactions between β-amyloid and central cholinergic neurons: implications for Alzheimer's disease. J Psychiatry Neurosci. 2004;29:427–41.

[11] Hari E, Kurt E, Bayram A, et al. Volumetric changes within hippocampal subfields in Alzheimer's disease continuum. Neurol Sci Off J Ital Neurol Soc Ital Soc Clin Neurophysiol. 2022;43:4175–83.

[12] de Flores R, La Joie R, Chételat G. Structural imaging of hippocampal subfields in healthy aging and Alzheimer's disease. Neuroscience. 2015;309:29–50.

[13] Mu Y, Gage FH. Adult hippocampal neurogenesis and its role in Alzheimer's disease. Mol Neurodegener. 2011;6:85.

[14] Basso M, Yang J, Warren L, et al. Volumetry of amygdala and hippocampus and memory performance in Alzheimer's disease. Psychiatry Res Neuroimaging. 2006;146:251–61.

[15] Ridha BH, Barnes J, Bartlett JW, et al. Tracking atrophy progression in familial Alzheimer's disease: a serial MRI study. Lancet Neurol. 2006;5:828–34.

[16] Wang PN, Lirng JF, Lin KN, et al. Prediction of Alzheimer's disease in mild cognitive impairment: a prospective study in Taiwan. Neurobiol Aging. 2006;27:1797–806.

[17] Pennanen C, Kivipelto M, Tuomainen S, et al. Hippocampus and entorhinal cortex in mild cognitive impairment and early AD. Neurobiol Aging. 2004;25:303–10.

[18] Scher AI, Xu Y, Korf ESC, et al. Hippocampal shape analysis in Alzheimer's disease: a population-based study. Neuroimage. 2007;36:8–18.

[19] van de Pol LA, Hensel A, van der Flier WM, et al. Hippocampal atrophy on MRI in frontotemporal lobar degeneration and Alzheimer's disease. J Neurol Neurosurg Psychiatry. 2006;77:439–42.

[20] Sandstrom CK, Krishnan S, Slavin MJ, et al. Hippocampal atrophy confounds template-based functional MR imaging measures of hippocampal activation in patients with mild cognitive impairment. AJNR Am J Neuroradiol. 2006;27:1622–7.

[21] Head D, Snyder AZ, Girton LE, et al. Frontal-hippocampal double dissociation between normal aging and Alzheimer's disease. Cereb Cortex. 2005;15:732–9.

[22] Barnes J, Scahill RI, Schott JM, et al. Does Alzheimer's disease affect hippocampal asymmetry? Evidence from a cross-sectional and longitudinal volumetric MRI study. Dement Geriatr Cogn Disord. 2005;19:338–44.

[23] Teipel SJ, Pruessner JC, Faltraco F, et al. Comprehensive dissection of the medial temporal lobe in AD: measurement of hippocampus, amygdala, entorhinal, perirhinal and parahippocampal cortices using MRI. J Neurol. 2006;253:794–800.

[24] Stang A. Critical evaluation of the Newcastle-Ottawa scale for the assessment of the quality of nonrandomized studies in meta-analyses. Eur J Epidemiol. 2010;25:603–5.

[25] Koutsodendris N, Nelson MR, Rao A, et al. Apolipoprotein E and Alzheimer's disease: findings, hypotheses, and potential mechanisms. Annu Rev Pathol. 2022;17:73–99.

[26] Ogbodo JO, Agbo CP, Njoku UO, et al. Alzheimer's disease: pathogenesis and therapeutic interventions. Curr Aging Sci. 2022;15:2–25.

[27] Solch RJ, Aigbogun JO, Voyiadjis AG, et al. Mediterranean diet adherence, gut microbiota, and Alzheimer's or Parkinson's disease risk: a systematic review. J Neurol Sci. 2022;434:120166.

[28] Giau VV, Bagyinszky E, An SSA. Potential fluid biomarkers for the diagnosis of mild cognitive impairment. Int J Mol Sci. 2019;20:4149.

[29] Gomez-Isla T, Price JL, McKeel DW, et al. Profound loss of layer II entorhinal cortex neurons occurs in very mild Alzheimer's disease. J Neurosci. 1996;16:4491–500.

[30] Braak H, Braak E. Neuropathological stageing of Alzheimer-related changes. Acta Neuropathol (Berl). 1991;82:239–59.

[31] Raskin J, Cummings J, Hardy J, et al. Neurobiology of Alzheimer's disease: integrated molecular, physiological, anatomical, biomarker, and cognitive dimensions. Curr Alzheimer Res. 2015;12:712–22.

[32] Sakaguchi Y, Sakurai Y. Left-right functional difference of the rat dorsal hippocampus for short-term memory and long-term memory. Behav Brain Res. 2020;382:112478.

[33] Kim TA, Syty MD, Wu K, et al. Adult hippocampal neurogenesis and its impairment in Alzheimer's disease. Zool Res. 2022;43:481–96.

[34] Swanson CJ, Zhang Y, Dhadda S, et al. A randomized, double-blind, phase 2b proof-of-concept clinical trial in early Alzheimer's disease with lecanemab, an anti-Aβ protofibril antibody. Alzheimers Res Ther. 2021;13:80.